

## Non-Recurrent Laryngeal Nerve (NRLN): A rare anatomical anomaly of the recurrent laryngeal nerve

Nagesh Madnoorkar<sup>1\*</sup>; Apurva Raina<sup>2</sup>

<sup>1</sup>Surgical Oncologist, Namco Charitable Trust's Cancer Hospital, Nashik, India.

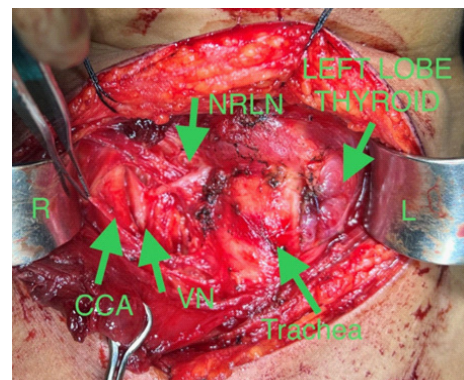
<sup>2</sup>Fellow in H & N Oncology, Namco Charitable Trust's Cancer Hospital, Nashik, India.

**Received Date** : Oct 03, 2022  
**Accepted Date** : Nov 16, 2022  
**Published Date** : Dec 09, 2022  
**Archived** : [www.jcmimagescasereports.org](http://www.jcmimagescasereports.org)  
**Copyright** : © Nagesh Madnoorkar 2022

**\*Corresponding Author:** Nagesh Madnoorkar, Surgical Oncologist, Namco Charitable Trust's Cancer Hospital, Nashik, India.  
E-mail: [nageshmadnoorkar@gmail.com](mailto:nageshmadnoorkar@gmail.com)

### Clinical Image

A 34-year young lady with a right-sided euthyroid nodule of 3x5 cm size for one year visited our clinic for surgery. FNAC was reported as colloid goiter. The right hemi-thyroidectomy surgery was planned. Intraoperatively while dissecting the right thyroid lobe, we could not find the right recurrent laryngeal nerve in its normal course, but we found a cord white-like structure running transversely & entering the larynx at the level of the cricothyroid muscle. We dissected it till its origin from the right vagus nerve in the neck. So, this was Non-recurrent laryngeal nerve (NRLN) which is a rare anatomical anomaly of the Recurrent Laryngeal Nerve (RLN) which arises higher in the neck and runs a course directly to the larynx as the NRLN without looping around the vessels in the chest. This intraoperative image is showing right-sided neck structures after removal of the right thyroid lobe & isthmus. The labeled structures in the image from right to left are the common carotid artery (CCA), Vagus Nerve (VN), Non-recurrent laryngeal nerve (NRLN), trachea & left lobe of the thyroid gland. Her post-operative recovery was good without any voice change. The final histopathology report was suggestive of colloid goitre.



**Citation:** Nagesh Madnoorkar. Non-Recurrent Laryngeal Nerve (NRLN): A rare anatomical anomaly of the recurrent laryngeal nerve. J Clin Med Img Case Rep. 2022; 2(6): 1317.