

Pott's puffy Tumor: A case report

Birgach N^{1*}; Attibbi M¹; Fakiri KEL¹; Rada N¹; Draiss G¹; Bouskraoui M¹; Rochdi Y²; Nouri H²; Raji A²; Ouazzani S³; Belghmaidi S³; Hajji I³; Moutaouakil A³

¹Pediatric A Department, Mohammed VI University Hospital, Marrakech.

²ORL and cervico-facial Department, Mohammed VI University Hospital, Marrakech.

³Ophthalmology Department, Mohammed VI University Hospital, Marrakech.

Received Date : Jan 31, 2023
Accepted Date : Feb 14, 2023
Published Date : Feb 16, 2023
Archived : www.jcmimagescasereports.org
Copyright : © Birgach N 2023

***Corresponding Author:** Birgach N, Pediatric A Department, Mohammed VI University Hospital, Marrakech.
 E-mail: birgachnada@gmail.com

Keywords: Pediatric, infectiology, cellulitis, empyema, sinusitis

Introduction

Pott puffy tumor is a rare entity, characterized by the association of a subperiosteal abscess and osteomyelitis of the frontal bone. It is often secondary to frontal sinusitis or trauma. We report the case of a 14-year-old child who presented with a Pott's tumor following frontal sinusitis, complicated by subdural empyema. He was successfully treated with antibiotic therapy and percutaneous drainage of the frontal abscess.

Patient and Methods

A 14-year-old patient presented to the pediatric A department for left orbital and frontal swelling evolving for 10 days, without any notion of trauma. The onset of the symptoms was marked by headaches and nasal congestion, complicated after 4 days left frontal and homolateral palpebral swelling (**Figure 1**). All evolving in a context of apyrexia.

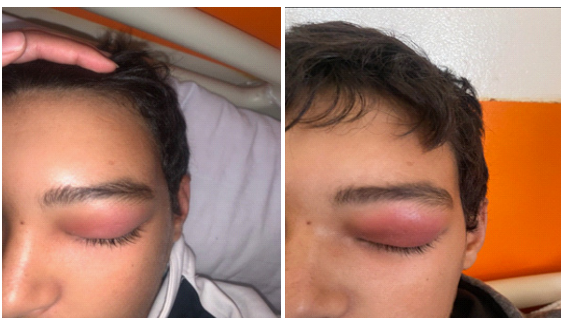

Figure 1: Frontal and orbitary tumefaction.

Clinical examination finds a patient who presents with hot and painful red palpebral and frontal tumefaction on palpation without damage to the oculomotor muscles or loss of visual acuity or neurological deficit with on rhinoscopy the presence of pus in the left middle meatus with on the biological assessment a hyperleukocytosis at 14,000 polymorphonuclear neutrophil with a CRP of 157. The hemoglobin and platelet counts were correct. Enhanced cerebro-orbital CT revealed pansinusitis complicated by left orbital cellulitis, left frontal osteitis and ipsilateral frontal cerebral empyema (**Figure 2**).

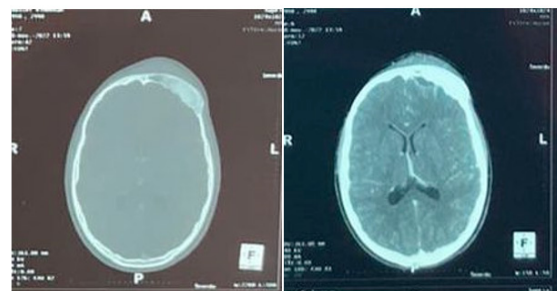


Figure 2: Pansinusitis complicated by left orbital cellulitis, left frontal osteitis and ipsilateral frontal empyema.

Percutaneous drainage of the abscess under the periosteum revealed gram-positive cocci in a chain. The patient was treated by ceftriaxone, ciprofloxacin and metronidazole for 21 days intravenous then switched by ciprofloxacin orally for 6 weeks. Surgical treatment was not indicated at this stage. The evolution was marked by a decrease in the inflammatory swelling with the possibility of palpebral opening after one week.

Citation: Birgach N. Pott's puffy Tumor: A case report. *J Clin Med Img Case Rep.* 2023; 3(1): 1375.

Discussion

Pott's puffy tumor, described by British surgeon Sir Percival Pott, is a polymicrobial infection that has become less common with adequate antibiotic treatment [1]. The term tumor refers to one of the 4 components of the inflammation (tumor) and not neoplasia [1]. Although it may be secondary to head trauma, it generally occurs following untreated or poorly treated frontal sinusitis [1]. This pathology is frequently seen in patients between 6-15 with a male predominance [1], due to increased vascularization and growth of the frontal sinuses at this age [1].

Frontal sinusitis can have intra and extra cranial complications following hematogenous dissemination, through the rich diploic venous networks and septic embolism [1,2], or the direct extension of infection, through the posterior wall causing epidural/subdural empyema, brain abscess, or meningitis, through the anterior wall causing subperiosteal abscess, or through the inferior wall with orbital complications [1,2]. Note that the most common orbital complications, occurring in 29% of cases, are preseptal and periorbital cellulitis. However, intraorbital abscesses are very rare [2]. The most common clinical signs are forehead swelling, headache, fever, nasal congestion or purulent/non-purulent secretions [1,3,4]. A soft, erythematous forehead swelling associated with fever is considered pathognomonic for Pott's tumour [1].

In some cases fever may be absent, and other signs may be associated including orbital swelling, nausea/vomiting and meningeal syndrome [1]. In our case, the patient presented to the emergency department for two frontal and orbital swellings with a history of headaches and nasal congestion. Fever was absent in our setting. He subsequently benefited from an injected cerebral-ocular CT scan, although MRI remains the examination of choice with its high soft tissue resolution, best characterizing the extent of the infection [1,5,6] CT showed pansinusitis complicated by osfrontal osteomyelitis, frontal lobe empyema and preseptal cellulitis.

The literature has confirmed that intracranial complications, with or without bone erosion, have been observed in 60% to 85% of cases [5,6] and may be asymptomatic until late in their evolution, especially when "silent" areas of the central nervous system such as the frontal lobe are involved [6].

The most common microorganisms are non-enterococci streptococci (47%), anaerobic bacteria (28%), staphylococci (22%) [7]. In our case, the culture was sterile, but direct examination revealed objective a gram positive cocci in chain.

The management of swollen pott's tumor is multidisciplinary; it consists of medical treatment, with broad-spectrum antibiotic therapy administered intravenous as soon as possible. The combination of ceftriaxone and clindamycin can be used to treat frontal sinusitis. In the case of *Staphylococcus aureus* (MRSA) which is generally resistant to clindamycin, vancomycin should be used in addition to ceftriaxone [8-10]. Combina-

tion therapy with vancomycin, ceftriaxone, and metronidazole covers most intracranial pathogens complicating acute bacterial sinusitis. In this case, metronidazole was chosen to be added to ceftriaxone and ciprofloxacin initially because of its good diffusion in the bones. A previous study showed that sinus related intracranial epidural abscesses in children could be managed without neurosurgical procedures in the setting of adequate sinus drainage, appropriate antibiotic therapy and minimal extradural mass effect from the abscess [11].

Conclusion

Although rare, Pott's tumor, frontal osteomyelitis, is a severe complication of frontal sinusitis. It can still occur despite the use of antibiotics and requires surgical treatment with drainage of the abscess and filling of the frontal sinus with different materials. It rarely progresses to intracranial extension potentially fatal.

References

- Sandoval JI, De Jesus O. Pott Puffy Tumor. In: Stat Pearls. Treasure Island (FL): StatPearls Publishing. 2022. PMID: 32809624.
- Elif Gozgec, Hayri Ogul, Korhan Kilic. Pott's Puffy Tumor with Intraorbital Abscess. *Rev Soc Bras Med Too.* 2022; 55: e0126-2022. PMID :10.1590/0037-8682-0126-2022.
- Liliana Costa, Laurentino Mendes Leal, Fernando Vales. Pott's edematous tumor: rara complicação da sinusitis. *Braz J Otorhinolaryngol.* 2020; 86(6): 812-814. PMID:10.1016/j.bjorl.2016.08.005
- Song MW, Montovano M, Kubiak A, Khalid S, Ellner J. Pott's Puffy Tumor: Intracranial Extension Not Requiring Neurosurgical Intervention. *Cureus.* 2020; 12(8): e10106. PMID: 10.7759/cureus.10106.
- Pranav Sharma, Salil Sharma, Nishant Gupta et al. Pott puffy tumor. *Proc (Bayl University Med Cent).* 2017; 30(2): 179-181. PMID:10.1080/08998280.2017.11929575
- İbrahim Ketenci, Yaşar Ünlü, Bülent Tucer, Alperen Vural. The Pott's puffy tumor: a dangerous sign for intracranial complications. *European Archives of Oto-Rhino-Laryngology.* 2011; 268: 1755-1763. PMID :10.1007/s00405-011-1660-5
- Adetunji Adejumo, Olusegun Ogunlesi, Ameera Siddiqui, et al. Pott Puffy Tumor Complicating Frontal Sinusitis. *The american journal of the medical sciences.* 2010; 340(1): P79 PMID :10.1097/MAJ.0b013e3181b5b5b5
- Rachel Tattersall, Prof Robert Tattersall. Pott's puffy tumor. *The lancet.* 2002; 359(9311): 989-1078. 10.1016/S0140-6736(02)08098-4.
- Bih-Yu Tsai, Kuang-Lin Lin, Tzou-Yien Lin. Pott's puffy tumor in children. *Childs Nerv Syst.* 2010; 26(1): 53-60. PMID:10.1007/s00381-009-0954-z

10. S Ibarra, Aguirrebengoa K, Pomposo I, et al: Osteomyelitis of the frontal bone (Pott's puffy tumor). A report of 5 patients. 1999; 17(10): 489-92. PMID: 10650643.

11. Heran, Navraj Singh, Steinbok, et al: Conservative Neurosurgical Management of Intracranial Epidural Abscesses in Children. Neurosurgery. 2003; 53(4): 893-898 .10.1227/01.NEU. PMID: 0000084163.51521.58