

## An illustration of clinical warts before and after treatment with the unani kit medicines in general OPD: A case study

Humaira Bano<sup>1\*</sup>; Nikhat Sheikh<sup>2</sup>; Sidra<sup>3</sup>

<sup>1</sup>Colocation Research Center, RRIUM, Mumbai, J.J. Hospital, Byculla, Mumbai, India.

<sup>2</sup>Regional Research Institute of Unani Medicine, Kharghar, Navi Mumbai, India.

<sup>3</sup>Department of J -13, Extn, Ramesh Park Laxmi Nagar, Delhi, India.

**Received Date** : May 23, 2023  
**Accepted Date** : July 05, 2023  
**Published Date** : July 12, 2023  
**Archived** : [www.jcmimagescasereports.org](http://www.jcmimagescasereports.org)  
**Copyright** : © Humaira Bano 2023.

**\*Corresponding Author:** Humaira Bano, Department of Colocation Research Center, RRIUM, Mumbai, J.J. Hospital, Byculla, Mumbai, India.  
Email: banu786.mau@gmail.com

### Abstract

The Unani system of medicine is an ancient, rich, and comprehended system of medicine, with knowledge propounded in the course of complicated, chronic, and rare disease treatments. The aim of this study is to bring its effectiveness and safety outcomes to light. This is a case study based on a 9-year-old boy, with complaints of a small growth on the little finger, which was cured with 100% effectiveness with the Unani kit medicine of Majoon Ushba and Habbe Musaffi khoon and sprinkling powder of Mazu (*Quercus infectoria Oliv*), Shibbe-yamani (Alum), and sandal wood powder. It creates a hypothesis to bring a clinical trial to a large scientific scale for better and more significant results.

**Keywords** : Unani kit medicines; Warts; Masāmīr; Case study.

### Introduction

Masāmīr/Tha'ālī are Arabic words used in the Unani System of medicine for a diseased condition called warts. Indeed, it is a hard, grainy skin growth fastened in between the dermis and underneath muscles, its colour is whitish, it is oval or rounded in shape, and it is placed inversely in the skin as a nail; that's the reason it is called Masāmīr [1]. Its commonest site is the fingers of the hands and soles, because this person gets trouble walking and touching [1]. Type of mass hard growth on the body, when its margin is rounded to be called Masāmīr (nail), but meandering and irregular imagination is called Qarn (corn/horn). Its material is thick, phlegmatic, and sticky [2].

**Treatment in the Unani System of Medicine:** The Unani System of Medicine believed in the treatment of evacuating waste and restoring the imbalanced temperament of the organ. So, Tanqya-e-Sawda wa Balgha (evacuation of black bile and phlegm) Rehydrate and strengthen the body with a nutrition supplement such as Ma-ul-jubn (whey), which is considered highly useful in the warts [1].

Second: An Application of Mazu (*Quercus infectoria Oliv*), Shibbe-yamani (Alum), and shahm-e- Hanzal (*Citrullus colocynthis Shrad*) sandal wood (*Santalum album*), and Murdar sang (Red lead) are useful [1-4].

In recent studies, this is a common wart also known as *Verruca vulgaris*, a dermatological condition that causes small, fleshy

growths on the skin. They are most often found on the hands or fingers and are caused by an infection with certain types of human Papillomavirus (HPV).

When a virus comes into contact with the skin, it may cause warts. Children are susceptible to developing them due to weak defences. Many skin warts contain a number of black dots that resemble little seeds. In integrative medicine, it is advised to use a chemical called cantharidin on the wart, which causes a blister to form beneath the growth. When the skin on the top of the blister dies, it contains part of the wart and can be removed, or other options include surgical removal of it [5].

Treatment for warts is not always completely effective, and a wart will sometimes return after following treatment with salicylic acid, cryotherapy (freezing the skin cells), or chemical treatments [6,7].

**Objectives:** To present a case study of small warts on the hand of a child with successful, safe, and non-recurrent treatment, and to conserve from a surgical, chemical, and painful treatment.

### Method of study

A 9-year-old male child came with a small, firm growth in his right hand on the base of his little finger. He complained of a small growth with pain, itching, and problems writing with

**Citation:** Humaira Bano. An illustration of clinical warts before and after treatment with the unani kit medicines in general OPD: A case study. J Clin Med Img Case Rep. 2023; 3(4): 1488.

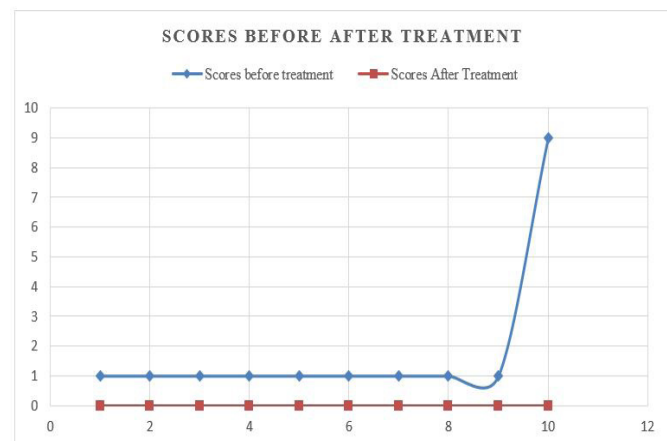that hand. For treatment, he consulted a family doctor and got advice to remove it through a small surgical procedure. The mother of the child did not agree to go through with it, and she was in great worry for this small growth because of its unseen impact on the hands and disfiguring future. It might be a big problem as the child has difficulty writing, which may hamper the school's performance. She wanted a safe, cheap, and permanent solution. She turned to the Co-location Research Centre of J.J. Hospital Compound in Byculla, Mumbai. He was interrogated for bowel habits, urination and diet habits, worm infestations, and any allergic reactions. The patient was examined thoroughly, and he was given treatment with OPD-based Unani kit medicines for 15 days. He was called for the follow-up after two weeks. The medicine's effect was recorded, and the child's mother agreed willingly to prepare a case study for publication. For the purpose of grading, all complaints are assigned a number to count them, and after treatment, the number counts.

Patient was given Habbe musaffi khoon 1Tab BD for 15 days; Majoon Ushba 4 gm BD for 15 days 9 patient's report and photograph shows that the effect of medicine is absolutely effective.

**Common complaints:** Scores assigned by asking questions every positive answer assigned one mark and negative 0 before

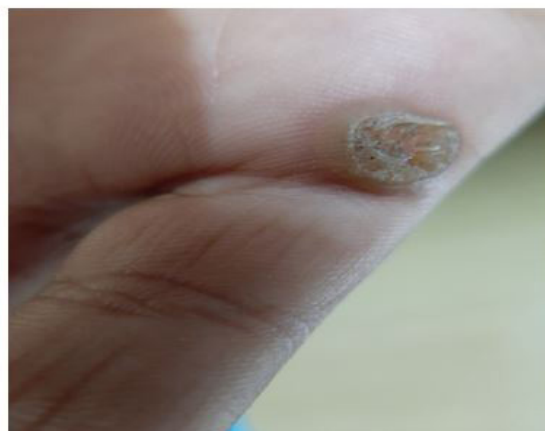**Table 1:** Scores before and after treatment.

Before treatment	Scores before treatment	Scores After Treatment
Small, raised skin growths.	01	0
Oval or round in shape.	01	0
Rough to the touch.	01	0
Hard around the edges and softer in the middle.	01	0
Speckled with small black dots or seeds.	01	0
Itching and irritating.	01	0
Pain.	01	0
Difficulty in writing notes.	01	0
Disfiguring the hands.	01	0
Total	09	0

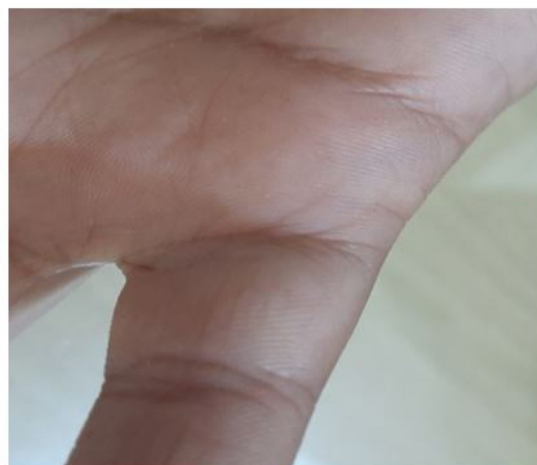

**Graph:** Graph showing scores before and after treatment.

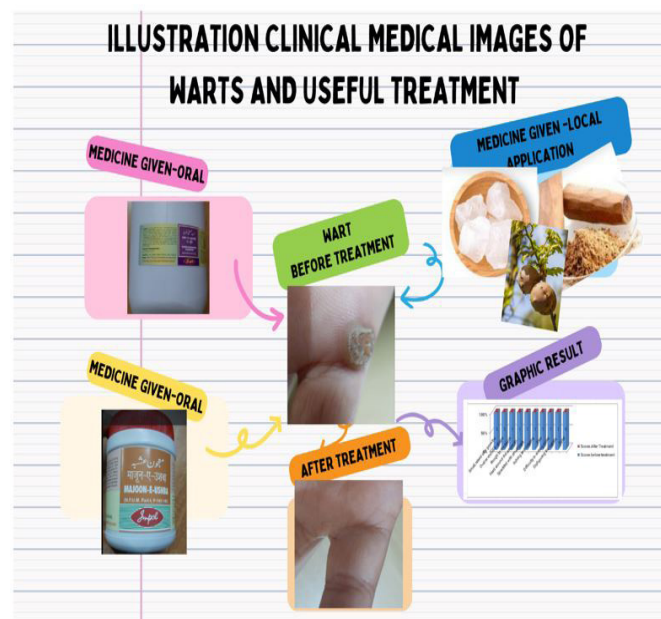
(A) Before treatment



(B) After treatment



**Figure 1:** 9 years old boy hand's warts



**Figure 2:** Infographic Abstract.

and after treatment.

## Result

Unani kit medicines are effective and safe in the treatment of warts, there is no recurrence, after six month follow-up and examination patient was happy and healthy with no more growth or any complaints and apprehension for future performance.

## Conclusion

Study concluded that, warts can be treated with the Unani medicine after giving systemic as well local application too. A clinical trial on a large scale can be done to further study on a scientific scale to see its effects in all possible types of warts, As it is known a small or multiple small growth bothered allots to the people who afflicted with kind of grainy growth in their skin.

**Glossary:** IUMT-5.13.83 warts Round hard eruption on external surface of skin Tha'ālīl. IUMT-5.13.84 warts with peduncles an eruption with pointed tip, may produce pain when touched Masāmīr [8,9].

## References

1. Jūrjānī Mohammad Ismail, Tarjuma Zakheera-e-Khwarzam Shahi. Translated by Munshi Naval Kishore. Lucknow. 1903; 7: 37.
2. Ibn-Al-Quff, Aminud-daula Abul-furj ibnul quff Al-masihi, Kitab-Al-Umdah fil jarahat. Urdu Central Council Research in Unani Medicine Ministry of Health and Family welfare Govt. of India New Delhi. 1896; 1: 177.
3. Kabiruddin, Mohammad Biyadh-e-kabeer Hikmat book depot Hyderabad Dakin. 1935; 1: 42.
4. Abūl Hasan Ahmad Bin Muhammad Tabrī 'Al-Mūalijāt-Būqratīyaurdu' CCRUM, New Delhi. 1997; 2: 214-215.
5. Warts: 10 Answers to Frequently Asked Questions Written by WebMD Editorial Contributors Medically Reviewed by Dan Brennan. 2022.
6. <https://www.nhsinform.scot/illnesses-and-conditions/skin-hair-and-nails/warts-and-verruucas>.
7. Common Warts Written by Ada's Medical Knowledge Team Updated on September 14, 2022.
8. International standard terminologies on Unani medicine WHO international standard terminologies on Unani medicine. World Health Organization 2022.
9. Anonymous, NFUM. Central Council Research in Unani Medicine Ministry of Health and Family welfare Govt. of India New Delhi. 2008; 14.